

NAME: _____

HST 130 – NEUROBIOLOGY 200

BLOCK II: NEUROANATOMY

This exam contains 80 questions, each worth 1 point. Please make sure that you clearly indicate your choice (circling the letter in Parts 1 and 4 or writing the letter from the APPROPRIATE list in Parts 2 and 3).

PART 1 (25 pts):

For the following questions, please circle the BEST answer:

- A lesion in the left medial lemniscus:
- A) produces loss of pain and temperature sense on the left side of the body
 - B) produces loss of pain and temperature sense on the right side of the body
 - C) produces loss of vibration and position sense on the left side of the body
 - D) produces loss of vibration and position sense on the right side of the body
 - E) produces loss of auditory information from the right ear
2. A patient presents with marked weakness of his left arm, but he refuses to believe that his arm is paralyzed. When asked to copy a picture, using his right hand, he fails to accurately represent the left side of the image. His lesion is most likely in the:
- A) left frontal lobe
 - B) left occipital lobe
 - C) left parietal lobe
 - D) right parietal lobe
 - E) right frontal lobe
3. The major location of noradrenaline-producing neurons in the brain is the:
- A) pars compacta of the substantia nigra
 - B) pars reticulata of the substantia nigra
 - C) locus ceruleus
 - D) raphe nuclei
 - E) nucleus accumbens
4. Occlusion of an anterior cerebral artery would most likely lead to:
- A) contralateral homonymous hemianopsia
 - B) contralateral arm weakness
 - C) contralateral leg weakness
 - D) Wernicke's aphasia
 - E) contralateral facial weakness

5. Which of the statements about the deep cerebellar nuclei is correct?
- A) output from the dentate nucleus projects to ipsilateral VA/VL of thalamus
 - B) globose and emboliform nuclei send axons in the superior cerebellar peduncle
 - C) fastigial nucleus efferents exit primarily via the superior cerebellar peduncle
 - D) the lateral cerebellar hemispheres project primarily to the fastigial nuclei
 - E) the vermis projects primarily to the dentate nuclei
6. The thalamic fasciculus contains fibers merging from the:
- A) ansa lenticularis + cerebellum
 - B) lenticular fasciculus + ansa lenticularis
 - C) lenticular fasciculus + cerebellum + thalamus
 - D) lenticular fasciculus + ansa lenticularis + basal ganglia
 - E) ansa lenticularis + lenticular fasciculus + cerebellum
7. Hemisection of the spinal cord (Brown-Sequard syndrome) most often results in signs below the lesion best described as:
- A) ipsilateral paralysis and contralateral loss of pain and temperature
 - B) ipsilateral paralysis and contralateral loss of light touch and position sense
 - C) contralateral paralysis and ipsilateral loss of pain and temperature
 - D) contralateral paralysis and ipsilateral loss of light touch and position sense
 - E) contralateral paralysis and bilateral loss of pain and temperature
8. The paraventricular and supraoptic nuclei:
- A) produce releasing hormones which diffuse into the hypophyseal portal system
 - B) project to the posterior pituitary
 - C) lead to the production of LH and FSH
 - D) make hormones which eventually reach the anterior pituitary
 - E) each produce only one hormone: ADH
9. Choroid plexus can usually be found in:
- A) anterior (frontal) horn of lateral ventricle
 - B) inferior (temporal) horn of lateral ventricle
 - C) floor of the third ventricle
 - D) floor of the fourth ventricle
 - E) cauda equina

10. Fibers originating in the dorsal root ganglia above T6 travel in:
- A) the ipsilateral Clark's column
 - B) the ipsilateral spinothalamic tract
 - C) the contralateral spinocerebellar tract
 - D) the ipsilateral fasciculus gracilis
 - E) the ipsilateral fasciculus cuneatus
11. The major source of inputs to the caudate nucleus is
- A) globus pallidus
 - B) subthalamic nucleus
 - C) putamen
 - D) association areas of the cortex, like prefrontal cortex
 - E) motor and somatosensory cortex
12. Efferents from all of the following basal ganglia structures use inhibitory neurotransmitters EXCEPT:
- A) Caudate
 - B) Putamen
 - C) Globus pallidus interna
 - D) Subthalamic nucleus
 - E) Substantia nigra, pars reticulata
13. Which of the following fiber tracts carries efferents from globus pallidus interna to the thalamus:
- A) Ansa cervicalis
 - B) Stria terminalis
 - C) Subthalamic fasciculus
 - D) Ansa lenticularis
 - E) Lenticular nucleus
14. Which of the following statements is true regarding "motor thalamus" or motor control in the thalamus:
- A) Inputs from the basal ganglia go mostly to VA while inputs from cerebellum go mostly to VL.
 - B) Output from "motor thalamus" projects to the cingulate gyrus.
 - C) The medial lemniscus and spinothalamic tracts are the major sources of motor information.
 - D) The thalamic nuclei involved in motor function receive blood supply predominantly from ganglionic branches of the anterior cerebral artery.
 - E) None of the above.

15. The swinging flashlight test reveals constriction of the left pupil and dilatation of the right pupil when the light is swung in front of the left eye. When the light is swung in front of the right eye, the left pupil constricts and the right pupil remains dilated. The lesion is located in:
- A) Right optic nerve
 - B) Right oculomotor nerve
 - C) Left optic nerve
 - D) Left oculomotor nerve
 - E) Left superior colliculus
16. Pyramidal tract fibers project through all but which structure
- A) Corona radiata
 - B) Posterior limb of internal capsule
 - C) Cerebral peduncle
 - D) Pontine tegmentum
 - E) Lateral funiculus of the cord
17. The pupillary light reflex does not involve
- A) Optic tract
 - B) Posterior commissure
 - C) Optic radiation
 - D) Pretectal nuclei
 - E) Optic chiasm
18. The facial nerve
- A) Shares nucleus ambiguus with cranial nerves IX and X
 - B) Motor nucleus is located in the upper pons
 - C) Parasympathetic fibers originate in the inferior salivatory nucleus
 - D) As a motor nerve, exits the brainstem close to the midline
 - E) Receives innervation from both cortical hemispheres
19. Which of the following combinations is NOT a pair of directly connected structures:
- A) Nucleus gracilis and Ventroposteriolateral nucleus of the thalamus
 - B) Subthalamic nucleus and globus pallidus internal
 - C) Anterior nucleus of the thalamus and hippocampus
 - D) Cerebellar cortex and inferior olivary nuclei
 - E) Retina and superior colliculus
20. Which of the following is true:
- A) Vestibular nuclei are close to the midline
 - B) Climbing fibers reach cerebellum through inferior and superior peduncles
 - C) Red nucleus projects to contralateral motor cortex
 - D) Vestibular nuclei receive a cerebellar projection that bypasses deep nuclei
 - E) Parallel fibers run parallel to the plane of Purkinje cell dendrites

21. Primary sensory cortex is located in
- A) Lateral occipital lobe
 - B) Parietal lobe
 - C) Precentral gyrus
 - D) Cingulate gyrus
 - E) Frontal eye fields
22. The olfactory bulb
- A) Projects to sensory cortex through VA/VL of the thalamus
 - B) Projects to sensory cortex through VPL/VPM of the thalamus
 - C) Projects to the solitary tract so that smell and taste can be combined
 - D) Receives cholinergic innervation from the nucleus of the diagonal band
 - E) Shares a type of myelin with the oculomotor nerve
23. Impairment of position sense would be most likely to come from
- A) lesion of the ventral root
 - B) lesion of the dorsal horn
 - C) lesion of the posterior funiculus of the cord
 - D) lesion of the lateral funiculus of the cord
 - E) lesion of the anterior funiculus of the cord
24. Fibers in the fornix
- A) Mostly cross in the hippocampal commissure
 - B) Mostly pass posterior to the anterior commissure
 - C) Project to the nucleus of Papez
 - D) Extend into the temporal white matter as Meyer's loop
 - E) Give rise to the stria terminalis as they arch forward
25. Which of the following fiber tract/structure combinations is correct:
- A) Amygdala and stria medullaris
 - B) Oculomotor nucleus and medial forebrain bundle
 - C) Amygdala and the stria terminalis
 - D) Cingulate gyrus and the perforant path
 - E) Dorsomedial thalamus and mamillothalamic tract

PART 2 (22 pts):

For the following questions, please enter the BEST answer from the list of choices

For the following six (6) questions, please use the following list of choices:

- A) Upper midbrain
- B) Lower midbrain
- C) Upper pons
- D) Lower pons
- E) Dorsal medulla
- F) Ventral medulla

- 26. Decussation of the pyramidal tract
- 27. Nucleus for touch sensation on the forehead
- 28. Nucleus involved in looking to the right with the right eye
- 29. Origin of climbing fibers
- 30. Structure involved in generation of spatial map from auditory information
- 31. Nuclei from which the medial lemniscus originates

For the following six (6) questions, please choose the most appropriate nerve(s) from the list:

- A) Oculomotor nerve (III)
- B) Trigeminal nerve (V)
- C) Facial nerve (VII)
- D) Vestibulocochlear nerve (VIII)
- E) Glossopharyngeal nerve (IX)
- F) Vagus nerve (X)
- G) Hypoglossal nerve (XII)

- 32. Baroreceptors at the aortic arch
- 33. Afferent limb of the gag reflex
- 34. Carries fibers to the tensor tympanii muscle
- 35. Contains only autonomic and somatic motor fibers
- 36. Afferent limb of the blink (corneal) reflex
- 37. Innervates lacrimal gland for tear generation

For the following five (5) questions, please choose the most appropriate structure from this list:

- | | |
|--------------------------------------|---------------------------------|
| A) Ciliary ganglion | I) Nucleus ambiguus |
| B) Dentate gyrus | J) Nucleus of solitary tract |
| C) Dentate nucleus | K) Nucleus of spinal tract of V |
| D) Dorsal motor nucleus of the vagus | L) Septal nucleus |
| E) Entorhinal cortex | M) Septum pellicidum |
| F) Mamillary body | N) Superior cervical ganglion |
| G) Mesencephalic nucleus of V | O) Superior salivatory nucleus |
| H) Nucleus accumbens | P) Trigeminal ganglion |

38. Target of perforant pathway
39. First order sensory neurons for multiple modalities
40. Second order sensory neurons for taste from anterior 2/3 of tongue
41. Origin of cholinergic projection to hippocampus
42. Activated in order to vomit

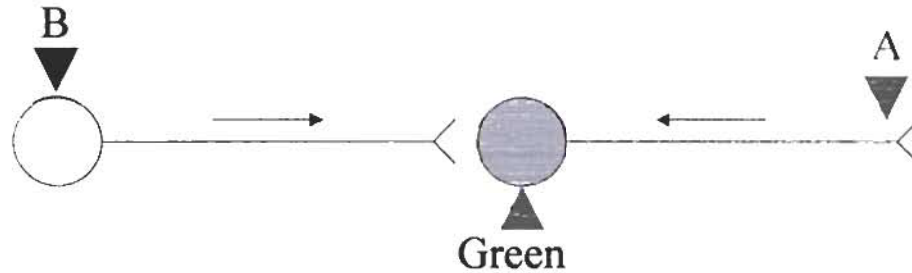
For the following five (5) questions, please choose the vessel most appropriate from this list:

- | | |
|--|---|
| A. Anterior cerebral artery | H. Posterior cerebral artery |
| B. Anterior choroidal artery | I. Posterior choroidal artery |
| C. Anterior communicating artery | J. Posterior communicating artery |
| D. Anterior inferior cerebellar artery | K. Posterior inferior cerebellar artery |
| E. Basilar artery | L. Superior cerebellar artery |
| F. External carotid artery | M. Recurrent artery of Heubner |
| G. Middle cerebral artery | N. Vertebral artery |

43. Somatosensory cortex corresponding to the ankle
44. Decussation of the pyramidal tract
45. Cochlear nuclei
46. Locus ceruleus
47. Primary auditory cortex

PART 3 (18 pts):

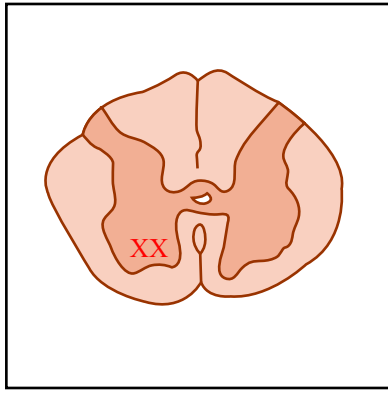
You have chosen a career as a neuroanatomist as a direct consequence of this course. A clever graduate student working in your lab has developed a pair of reagents for pathway tracking. Molecule A is collected by axons at the point of synaptic connection to their target and transported back to the cell body, while molecule B is taken up by neuronal cell bodies and transported to the synapse where it is released and it taken up by the post-synaptic cell. When both A and B end up in the same cell, they combine to create a green fluorescent complex.



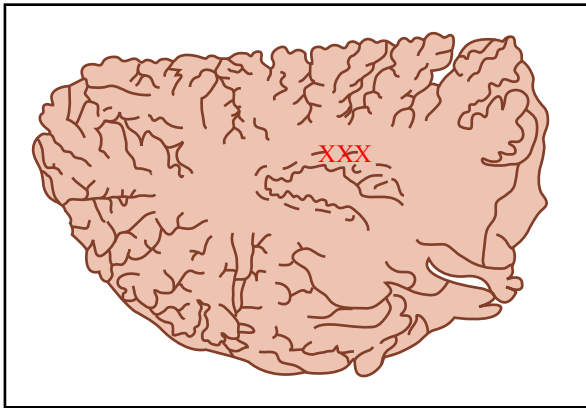
Beautiful pictures from these experiments are published on the cover of the issue of *Nature* containing your paper. The paper has 6 figures that show this system in operation (here reproduced as line drawings with the fluorescent signal represented by an "X"). Please provide the following information (site labeled; projection target [A]; input [B]) that would be required for each figure legend, using the following list of structures:

- | | | | |
|----|--------------------------------|-----|------------------------------|
| A. | Anterior horn | U. | Nucleus of cranial nerve III |
| B. | Arm muscle | V. | Nucleus of cranial nerve VI |
| C. | Broca's area | W. | Nucleus cuneatus |
| D. | Caudate nucleus | X. | Nucleus gracilis |
| E. | Cerebellar granule cell layer | Y. | Postcentral gyrus, lateral |
| F. | Cerebellar Purkinje cell layer | Z. | Postcentral gyrus, medial |
| G. | Cingulate gyrus | AA. | Precentral gyrus, lateral |
| H. | Cochlear nucleus | BB. | Precentral gyrus, medial |
| I. | Dentate gyrus | CC. | Prefrontal cortex |
| J. | Dentate nucleus | DD. | Putamen |
| K. | Dorsal root ganglion | EE. | Red nucleus |
| L. | Dorsomedial thalamus | FF. | Striate cortex |
| M. | Entorhinal cortex | GG. | Substantia nigra |
| N. | Fastigial nucleus | HH. | Subthalamic nucleus |
| O. | Globus pallidus, externa | II. | VA/VL of thalamus |
| P. | Globus pallidus, interna | JJ. | Vestibular nucleus |
| Q. | Heschl's gyrus | KK. | VPL of thalamus |
| R. | Inferior olive | LL. | Wernike's area |
| S. | Leg muscle | | |

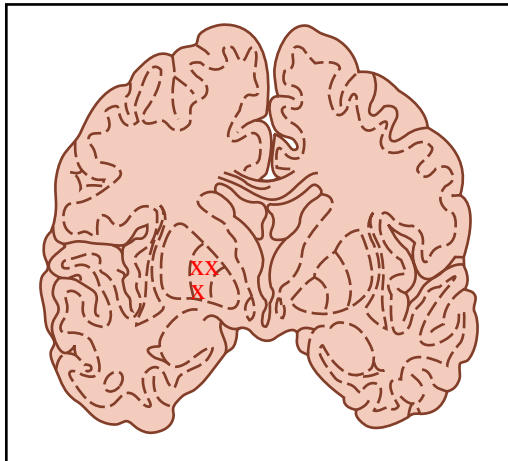(Because of the high level of connectedness of the nervous system, there may be more than one correct answer to each question)



- 48. Labeled structure:
- 49. Injection site for A:
- 50. Injection site for B:

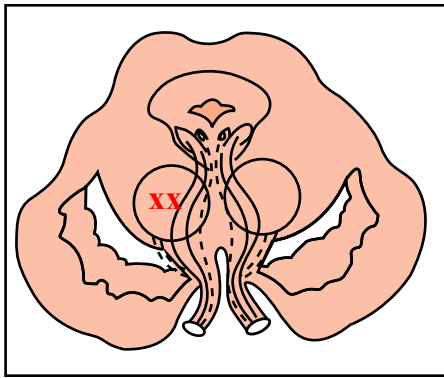


- 51. Labeled structure:
- 52. Injection site for A:
- 53. Injection site for B:

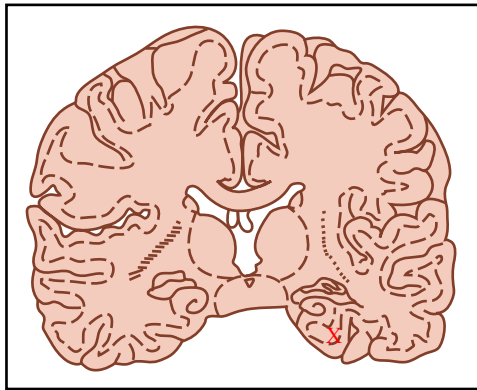


- 54. Labeled structure:
- 55. Injection site for A:
- 56. Injection site for B:

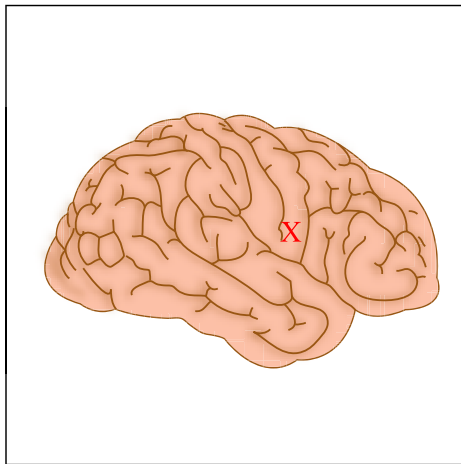
Figures courtesy of MIT OCW.



- 57. Labeled structure:
- 58. Injection site for A:
- 59. Injection site for B:



- 60. Labeled structure:
- 61. Injection site for A:
- 62. Injection site for B:



- 63. Labeled structure:
- 64. Injection site for A:
- 65. Injection site for B:

Figures courtesy of MIT OCW.

PART 4 (15 pts):

For the following questions, please use the follow answer guide:

- A. 1 and 3 are correct**
- B. 1, 2 and 3 are correct**
- C. 2 and 4 are correct**
- D. 4 is correct**
- E. none of the above combinations**

66. The habenula

- 1. is one of the few unpaired midline structures in the brain
- 2. is a thalamic association nucleus
- 3. projects to the hippocampus via the fasciculus retroflexus
- 4. receives input from the amygdala via the stria terminalis

A B C D E

67. Crossed projections include

- 1. nucleus gracilis to thalamus
- 2. trochlear nuclei to inferior oblique muscle
- 3. pontine nuclei to cerebellar hemisphere
- 4. facial nerve motor nucleus to muscles of the forehead

A B C D E

68. Regarding somatotopic organization:

- 1. Midline lesions on the upper pons might affect arms fibers from both medial lemnisci
- 2. In the dorsal columns, leg fibers are more lateral than arm fibers
- 3. In the medulla, arms fibers in the medial lemniscus are dorsal to leg fibers
- 4. In the lateral lemniscus, leg is more lateral than arm

A B C D E

69. Which of these statements are true about catecholaminergic nuclei

- 1. VTA projects to caudate while substantia nigra projects to putamen
- 2. Raphe nuclei in the pons provide the noradrenergic innervation of cortex
- 3. Locus ceruleus is located in the lower pons
- 4. Tyrosine hydroxylase is the rate limiting enzyme in catechol synthesis

A B C D E

70. In the visual pathways,

- 1. Cutting the left optic nerve leads to blindness in the left eye
- 2. The different layers of cells in the lateral geniculate correspond to different parts of visual space
- 3. In striate cortex, the center of visual space is located towards to occipital pole
- 4. Fibers from temporal retina cross in the optic chiasm

A B C D E

71. The superior olive

1. Lies in the ventral medulla
2. Projects to the cerebral hemisphere as climbing fibers
3. Receives afferents from the ipsilateral red nucleus
4. Sends fibers into the ipsilateral inferior cerebellar peduncle

A B C D E

72. CSF generated in the 4th ventricle can exit it through the

1. foramen of Magendie
2. cerebral aqueduct
3. foramen of Luschka
4. foramen of Munro

A B C D E

73. A circumferential mass impinging on the cervical spinal cord (C4-C7) from the outside is most likely to

1. involve the spinocerebellar tracts
2. involve the fasciculus gracilis more than cuneatus
3. cause upper extremity weakness (lower motor neuron pattern)
4. cause upper extremity weakness (upper motor neuron pattern)

A B C D E

74. Fibers of the superior cerebellar peduncle decussate in the

1. tectum
2. pontine tegmentum
3. basis pontis
4. midbrain tegmentum

A B C D E

75. In most people, blood vessels arising from the basilar artery include

1. superior cerebellar artery
2. quadrigeminal artery
3. anterior inferior cerebellar artery
4. posterior inferior cerebellar artery

A B C D E

76. On a coronal section of the brain, which of the following can appear adjacent to the temporal horn of the ventricle:

1. amygdala
2. caudate
3. hippocampus
4. thalamus

A B C D E

77. Fibers of the fornix synapse in

1. mamillary body
2. amygdale
3. nucleus accumbens
4. cingulate gyrus

A B C D E

78. In the autonomic nervous system,

1. sympathetic output originates in Clarke's nucleus in the thoracic cord
2. cells in the superior cervical ganglion synapse in the ciliary ganglion before reaching the pupil
3. Sympathetic fibers ascend from the cord with the spinal accessory nerve
4. parasympathetic and sympathetic systems leave the CNS at different levels

A B C D E

79. Basal ganglia projections include

1. Putamen to GPe
2. Caudate to GPi
3. Caudate to GPe
4. Subthalamic nucleus to thalamus

A B C D E

80. Association areas of cerebral cortex receive inputs from

1. relay nuclei of the thalamus
2. association areas of the thalamus
3. nucleus basalis of Meynert
4. multiple cortical areas

A B C D E